

# Thai Journal of Veterinary Medicine

**Country** Thailand

**Subject Area** Veterinary

**Subject Category** Veterinary (miscellaneous)

**Publisher** Chulalongkorn University

**Publication type** Journals

**ISSN** 01256491

**Coverage** 2008-ongoing

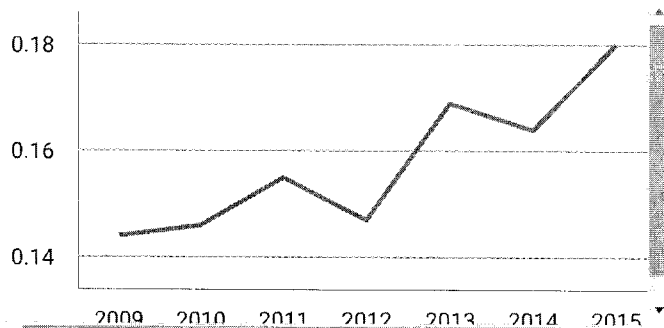
# 6

H Index

## Quartiles

Category	Year	Quartile
Veterinary (miscellaneous)	2009	Q4
Veterinary (miscellaneous)	2010	Q4
Veterinary (miscellaneous)	2011	Q4
Veterinary (miscellaneous)	2012	Q4
Veterinary (miscellaneous)	2013	Q3
Veterinary (miscellaneous)	2014	Q3
Veterinary (miscellaneous)	2015	Q3

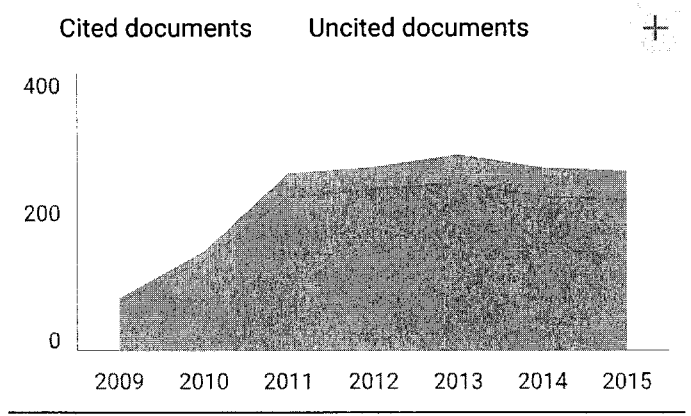
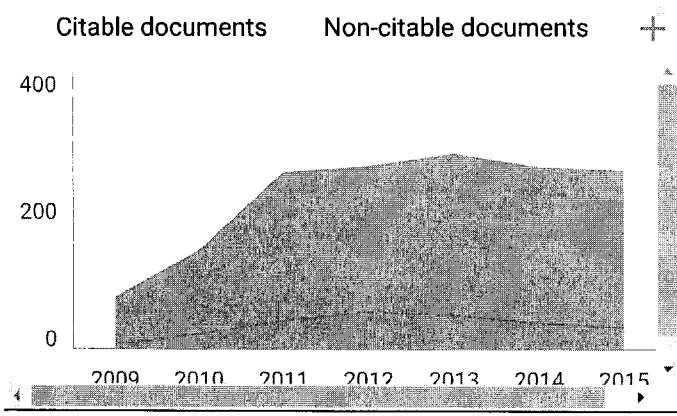
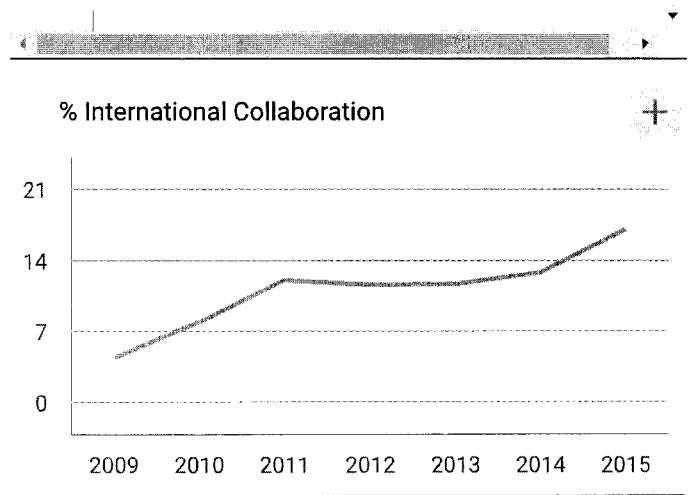
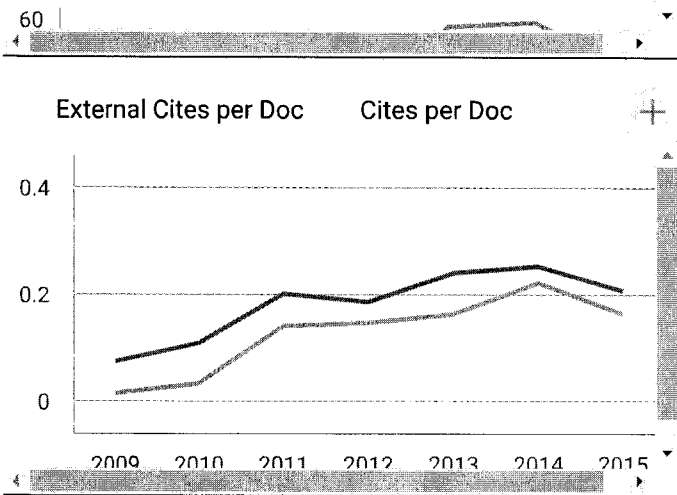
## SJR



## Citations per document

## Total Cites

## Self-Cites



Thai Journal of Veterinary Medicine

Indicator	2008-2015	Value
SJR		0.18
Cites per doc		0.15
Total cites		47

www.scimagojr.com

← Show this widget in your own website

Just copy the code below and paste within your html code:

```
<a href="http://www.scimag
```

Developed by:



Powered by:



Follow us on Twitter

Scimago Lab, Copyright 2007-2016. Data Source: Scopus®

# General Anesthesia, Utilizing Etorphine Hydrochloride and Azaperone with Supplementary Isoflurane Inhalation Anesthesia, for Gastro-esophageal Endoscopy in a Domesticated Asian Elephant (*Elephas maximus*): A case report

Nikorn Thongtip<sup>1,2</sup> Aumaporn Maikaew<sup>4</sup> Wanlaya Tipkantha<sup>3</sup> Daraka Thongthainan<sup>5</sup>  
Nicharee Income<sup>6</sup> Benjapol Lorsunyaluck<sup>1</sup> Pornchai Sunyathitiseree<sup>1,2</sup> Boripat Siriaronrat<sup>3</sup>  
Sumate Kamolnoranarth<sup>3</sup>

## Abstract

A 30-year-old female domestic Asian elephant (*Elephas maximus*) was referred to Kasetsart University Veterinary Teaching Hospital for investigation of an esophageal obstruction. "Vomiting" had been noted for several days before admission. Initial sedation was achieved by azaperone (80 mg), delivered intramuscularly (IM). Once sedated supporting straps and a sling were fitted, and weight-bearing support was provided by a crane. General anesthesia was induced using 2 mg etorphine hydrochloride (0.00066 mg/kg) by intravenous (IV) injection. Using the crane, she was lowered onto a thickly bedded area on the floor and placed in right lateral recumbency. Oxygen was initially provided via the trunk. Blind endotracheal intubation was unsuccessful until further two incremental doses of etorphine hydrochloride (0.5 and 1.5 mg) had been administered. Even though subsequently maintained on 5% isoflurane, a third increment of etorphine hydrochloride (1 mg) was required to fully abolish jaw tone. Following successful endoscopy for gastro-esophageal evaluation anesthesia was reversed through cessation of isoflurane and administration of naltrexone (500 mg by IM injection). Some reflexes including ear twitching and leg moving were noticed within 1 min and endotracheal extubation was carried out after 2 min, when jaw tone returned. First attempts at standing took place after 3 min, the elephant could stand with support after 8 min and was ambulatory at 11 min after reversal. The total time from sedation to independent walking was 1.16 hr.

**Keywords:** elephant, esophageal obstruction, general anesthesia

<sup>1</sup>Wildlife Unit, Veterinary Teaching Hospital, Kasetsart University, Kamphaengsaen, Nakorn Pathom, Thailand

<sup>2</sup>Department of Large Animal and Wildlife Clinical Sciences, Faculty of Veterinary Medicine, Kasetsart University, Kamphaeng Saen, Nakorn Pathom, Thailand

<sup>3</sup>Bureau of Conservation, Research and Education, Zoological Park Organization, Bangkok, 10300, Thailand

<sup>4</sup>Khaokeaw Open Zoo, Sriracha, Choburi, Thailand

<sup>5</sup>Faculty of Veterinary Medicine, Rajamangala University of Technology Tawan-Ok, Sriracha, Choburi, Thailand

<sup>6</sup>Livestock and Wildlife Hospital, Faculty of Veterinary Sciences, Mahidol University, Saiyok, Kanjanaburi, Thailand

\*Correspondence: fvetnit@ku.ac.th, nthongtip@yahoo.com

## Introduction

Due to their large body mass and perceived anesthetic risk, general anesthesia is not frequently performed in Asian elephants (*Elephas maximus*). For standing sedation, xylazine is a drug of choice for Asian elephants. Azaperone has been also used to tranquilize and translocate Asian elephant in India (Cheeran et al., 2002). For major surgery or complex diagnostic procedures maintenance of general anesthesia, potentially for long periods, is required. Historically, etorphine hydrochloride alone or in combination with acepromazine (Immobilon®, C-Veterinary Products, Leyland, Lancs, PR5 3QN) has been used in both African (*Loxodonta africana*) and Asian elephants worldwide (Jainudeen et al., 1971; Bongso et al., 1978; Schmidt, 1986; Kock et al., 1993; Sujit et al., 2005). General anesthesia using an etorphine hydrochloride and azaperone combination has been reported in African elephants (Dunlop et al., 1994; Still, 1993; Still et al., 1996; Stegmann, 1999). However, there is limited information about the use of etorphine hydrochloride and azaperone in combination in Asian elephants. The use of sequential etorphine hydrochloride injections with isoflurane inhalation has been reported in Asian elephants for extensive foot treatments and surgery (Fowler et al., 2000). In Thailand, general anesthesia using the combination of etorphine hydrochloride and acepromazine (Immobilon®) with subsequent inhalation halothane anesthesia for gastro-esophageal endoscopy of esophageal obstruction has been reported (Sujit et al., 2005). Opioid narcotics usually increase blood pressure. It is believed that this can lead to the potentially fatal "pink foam syndrome" in elephants (Honeyman et al., 1992; Raath, 1993; Fowler and Mikota, 2006; Horne and Loomis, 2007). "Pink foam syndrome" externally manifest as a pink froth from the trunk and is caused by pulmonary edema and capillary bleeding. Several reports recommend that azaperone can be combined with opioid narcotics in order to counteract the hypertensive effects that lead to this clinical syndrome (Hattingh et al., 1994). However, despite its potential attraction in eliminating anesthetic complications, the combination of sedation with azaperone by injection, induction with etorphine injection and maintenance with isoflurane has not yet been reported in Asian elephants. This case report describes the use of azaperone followed by etorphine hydrochloride by injection, and subsequent isoflurane by inhalation to maintain anesthesia, which successfully allowed gastro-esophageal endoscopy in an Asian elephant.

**Elephant signalments and supportive treatments:** A 30-year-old female domestic Asian elephant (*Elephas maximus*) was referred to Kasetsart University Veterinary Teaching Hospital (KUVTH) for full diagnostic work up due to a suspected esophageal obstruction. The history obtained indicated that previously, for several days, she had shown passive reflux of non-swallowed food and saliva. She had initially presented at and was then admitted to an animal hospital in Kanjanaburi. After one day, she was referred to KUVTH. On initial presentation at KUVTH

she was inappetent and appeared depressed. Saliva was drooling from the mouth. This was gauged to be of normal quantity, rather than hyper-salivation; however, it was not being swallowed. Based on experience, her bodyweight was estimated to be 3,000 kg. The elephant's body temperature was 36.1 °C. The pulse and respiratory rates were 35 beats and 8 breaths per minute, respectively. Her mucous membrane was pale pink. Her dry and withered skin was consistent with severe dehydration. Blood was collected from her ear vein. The hematology and blood chemistry profiles were shown on table 2. The elephant blood results revealed increase of PCV, Hb and creatinine, which correlated with severe dehydration. The elephant was also given 10 liters of fluid therapy (R-Acetate-5, Dextrose 5% in Acetated Ringer's Injection, General Hospital Products Public Co., Ltd., Pathum Thani, Thailand) via ear vein. The elephant was injected with long acting amoxicillin (Longamox®, Vetoquinol, Lure, France) at a total dose of 7,500 mg/day intramuscularly. Fifty ml of an injectable supplement containing butaphosphan and cyanocobalamin (Catosal®, Bayer Health Care, Kansas, USA) was given by IM injection.

**Elephant anesthesia and gastro-esophageal endoscopy:** After one day of physical examination, work-up and preparation, diagnostic anesthesia was performed. Reported doses for etorphine hydrochloride in Asian elephants are ranged between 0.001-0.004 mg/kg (Fowler, 1995; Kreeger et al., 2002, Nayar et al., 2002, Sujit et al., 2005). We have previously reported using a dose of 0.002 mg/kg (Sujit et al., 2005). This dose was used in an elephant without premedication. In this case, azaperone was used as a sedative. We considered the lowest reported rate of 0.001 mg/kg etorphine hydrochloride to be the most appropriate dosage. Furthermore, as the elephant was deemed to be compromised and weak, a decision was made to further lower the induction dose of etorphine hydrochloride to 0.00066 mg/kg; (a total dose of 2mg). To achieve general anesthesia, an intramuscular (IM) injection of azaperone (Azaperone, 100mg/mL; Kyron Prescriptions cc, South Africa) using a 18 Gx1.5 inch needle in the triceps of the left foreleg at a dose rate of 0.0266 mg/kg; a total of 80 mg (Cheeran et al., 2002) was performed. For record purposes, this injection was designated as time zero. In 18 min, sedation was deemed to have been achieved when the elephant showed no response to vigorous manual stimulation of the lateral thigh and when the trunk rested on the floor. At this point a combination of webbing straps and a sling were put in place and was supported by using a crane. General anesthesia was induced using etorphine hydrochloride (2 mg) injection intravenously (IV). 3 min post-injection the elephant was noticeably more subdued, with her weight being supported by the sling arrangement as she tried resting on the floor. Using the crane she was lowered onto a thickly-bedded area on the floor and placed on right lateral recumbency (Fig 1). Intravenous fluid (R-Acetate, Dextrose 5% in Acetated Ringer's Injection, General Hospital Products Public Co., Ltd., Pathum Thani, Thailand) was given via ear vein with IV catheter No.18 Gx1.5 inch. The flow rate was maximum. The eyes were lubricated

with chloramphenicol ointment (Cogetin®, General Drug House). A pulse oximeter (Nellcor N-180 □ Williamson Court, Louisville, KY) was attached to the ear. If the oxygen saturation was below 95%, oxygen was delivered using a tube via the trunk, with intermittent manual positive pressure ventilation. An attempt was made to manually insert a 30 mm endotracheal tube by blind technique (Fig 2). However, this failed as there was still jaw tone and the hand insertion initiated chewing reflex. The elephant was given two more doses (0.5 and 1.5 mg) of etorphine hydrochloride IV for jaw relaxation. Sufficient relaxation was achieved to facilitate endotracheal intubation. The endotracheal tube cuff was inflated and the tube was connected to an anesthetic machine delivering 5% isoflurane (Terrell™, Isoflurane, USP, MINRAD INC., Bethlehem, PA, USA) with 10 L/min of oxygen for maintenance. It was noted that, even with successful endotracheal intubation and isoflurane being delivered at 5%, there still remained a small

component of reflex chewing. Thus, an additional 1 mg increment of etorphine hydrochloride was administered intravenously. This was sufficient to allow endoscopy for gastro-esophageal evaluation. Gastro-esophageal endoscopy was undertaken, per os, using a 1.7 m long, 1 cm diameter flexible fiber optic video endoscope utilizing a light-source with the images being recorded with a video-processing circuit (PENTAX (EPM3300 and EC3830 fz). A 20 mm rubber tube was inserted and used to guide the endoscope through the pharynx into the esophagus. Good visualization was achieved for the whole of the esophagus. No obstruction was found. The stomach was too voluminous to be fully visualized, but was noted to contain large amounts of fluid and part-digested food. Based on these findings esophageal blockage and gastric impaction were ruled out. Treatment for gastritis was initiated and the medical condition resolved over the following month.




Figure 1 The use of straps, slings and crane to support during lateral recumbency




Figure 2 Blind endotracheal tube intubation technique




Figure 3 straps and crane support during reversal

On retraction of the endoscope no further isoflurane was delivered and an opioid antagonist, 500 mg naltrexone (Naltrexone, 50mg/mL; Kyron Prescription cc, South Africa), was administered intramuscularly. One minute after injection of the reversal agent, the elephant became progressively aroused and reflexes returned incrementally. Chewing reflex was detected within 2 min of reversal, prompting extubation of the endotracheal tube. The elephant tried to stand in 3 min and by 8 min the elephant could stand, relying the straps and crane (Fig 3). It was able to walk without support 11 min after reversal. The total time from sedation to independent walking was 1.16 hr (Table 1).

### Discussion

General anesthesia, using etorphine hydrochloride and azaperone by injection for induction with follow-up isoflurane by inhalation, permitted us to carry out gastro-esophageal endoscopy in an adult female domesticated Asian elephant. She became ataxic within 3 min of the first IV dose of etorphine hydrochloride and, with crane support, was in lateral recumbency in 5 min. This was in accordance to our previous report (Sujit et al., 2005). However, due to the persistence of jaw tone and a chewing reflex blind technique intubation was unsuccessful. A relative under-dose of etorphine hydrochloride at induction due to under-estimating body weight may be the cause. We had deliberately gone below the lowest dosage for etorphine hydrochloride in

correspondence to the use of azaperone and the animal's generally comprised physiology. Further, incremental, etorphine hydrochloride abolished the chewing reflex to the extent that it facilitated endotracheal intubation. However, even when isoflurane was being delivered at 5% via the endotracheal tube a further increment of etorphine hydrochloride was required to abolish completely the chewing reflex in order that we could undertake the endoscopic procedure. Our experience in using "full dose" of etorphine hydrochloride at induction worked well and permitted endotracheal intubation without additional increments of etorphine hydrochloride. In addition, we had previously used halothane rather than isoflurane. This may have aided our management of previous cases. The combination of etorphine hydrochloride and halothane had been successfully used by other practitioners (Fowler et al, 2000). In hindsight, we may have considered a larger induction dose of etorphine hydrochloride, but we had concerns for the elephant's general health and had erred on the side of caution. However, our objective was accomplished. We achieved using azaperone as a sedative and reactive management for this elephant under anesthesia. Having dedicated anesthetists for this procedure makes for a far safer intervention for all parties. This case demonstrates safe and efficacious use of azaperone followed by etorphine hydrochloride and maintenance of general anesthesia by isoflurane in an compromised adult domesticated Asian elephant.

Table 1 Anesthetic summary record during general anesthesia for gastro-esophageal endoscopy

Time (min.)	Drugs	Monitor			Notes
		Pulse rate (beats/min)	Respiration rate (breaths/min)	Body temperature (°C)	
0	Azaperone (80 mg, IM)	NA	NA	NA	IM injection
18					Sedation noted, slings and straps fitted
21	Etorphine (2 mg, IV)				IV fluid therapy also commenced with maximum flow rate
24					Salivation and ataxia noted
26		44	13		Lowered into full right lateral recumbency
29					Oxygen supplemented via intranasal tube
30					Intubation failed - chewing reflex
34	Etorphine (0.5 mg, IV)				
38	Etorphine (1.5 mg, IV)	48	12		
41					Successful endotracheal intubation
48	isoflurane (5%, ET)	44	12		Stable but chew reflex initiated when attempted endoscopy
50	Etorphine (1 mg, IV)	40	12	35.5	
51		36	12	36.1	Gastro-esophageal endoscopy commenced
59		36	10	35.8	Endoscopy concluded. Isoflurane stopped
66	Naltrexone (500 mg IM)	36	8		Opioid reversal
67					Chewing reflex noted and legs moving. Endotracheal tube extubated
69					Attempted to stand
74					Standing, supported by crane
76					Standing without support and walking

NA = Not available

### Acknowledgements

We thank Dr. Andrew Routh for critical editing this manuscript. We also thank the Faculty of Veterinary Medicine, Kasetsart University, Kamphaeng Sean Campus, for providing great support for this case study.

### References

- Bongso TA and Perera BMAO 1978. Observations on the use of etorphine alone and in combination with acepromazine maleate for immobilization of aggressive Asian elephants (*Elephas maximus*). Vet Rec. 102:(15):339-340.
- Cheeran JV, Chandrasekharan K, and Radhakrishnan K 2002. Tranquilization and translocation of elephants. J Indian Vet Assoc. 7:(3):42-46.
- Dunlop CI, Hodgson DS, Cambre RC, Kenny DE, and Martin HD 1994. Cardiopulmonary effects of three prolonged periods of isoflurane anesthesia in an adult elephant. J Am Vet Med Assoc. 205(10):1439-44.
- Fowler ME, 1995. Elephants. In: Restraint and handling of wild and domestic animals. Iowa State University Press, Ames, Iowa, USA. pp. 265-269.
- Fowler ME, Steffey EP, Galuppo L and Pascoe JR 2000. Facilitation of Asian elephant (*Elephas maximus*) standing immobilization and anesthesia with a sling. J Zoo Wildl Med. 31:(1):118-123.
- Fowler, M.E. and Mikota, S.K. 2006. Chemical restraint and general anesthesia, in Fowler ME, Mikota SK (eds): Biology, Medicine and Surgery of Elephants. Ames, IA, Blackwell Publishing, pp 91-110.
- Hattingh J, Knox CM and Raath JP 1994. Arterial blood pressure of the African elephant (*Loxodonta africana*) under etorphine anaesthesia and after remobilisation with diprenorphine. Vet Rec. 135:(19):458-459.

- Honeyman VL, Pettifer GR and Dyson DH 1992. Arterial blood pressure and blood gas values in normal standing and laterally recumbent African (*Loxodonta africana*) and Asian (*Elephas maximus*) elephants. *J Zoo Wildl Med.* 23(2): 205-210.
- Horne WA and Loomis MR 2007. Elephant and Hyrax, in West, F, Heard D, Caulkett N (eds): *Zoo Animal and Wildlife Immobilization and Anesthesia*. Blackwell Publishing, Ames, IA. pp 507-521.
- Jainudeen MR, Bongso TA and Perera BMOA 1971. Immobilization of aggressive working elephants (*Elephas maximus*). *Vet Rec.* 89:(26):686-688.
- Kreeger TJ, Arnemo JM and Raath JP 2002. In: *Handbook of wildlife chemical immobilization*. Wildlife Pharmaceuticals Inc., Fort Collins, Colorado, U.S.A., pp. 183-184.
- Kock MD, Martin RB and Kock N 1993. Chemical immobilization of free-ranging African elephants (*Loxodonta africana*) in Zimbabwe, using etorphine (M99) mixed with hyaluronidase, and evaluation of biological data collected soon after immobilization. *J Zoo Wildl Med.* 24:(1):1-10.
- Nayar KNM, Chandrasekharan K and Radhakrishnan K 2002. Management of surgical affections in captive elephants. *J Indian Vet Assoc.* 7:(3):55-59.
- Schmidt MJ 1986. Proboscidea (Elephants). In: Fowler, M.E. (Editor), *Zoo and wild animal medicine*. W.B. Saunders, Philadelphia, PA, USA pp. 884-923.
- Stegmann GF 1999. Etorphine-halothane anaesthesia in two five-year-old African elephants (*Loxodonta africana*). *J South Africa Vet Med Assoc.* 70:(4):164-166.
- Still J, Raath JP and Matzner L 1996. Respiratory and circulatory parameters of African elephants (*Loxodonta africana*) anesthetized with etorphine and azaperone. *J South Africa Vet Med Assoc.* 67:(3):123-127.
- Still J 1993. Etorphine-azaperone anaesthesia in an African elephant (*Loxodonta africana*). *J Vet Anesth.* 20:54-55.
- Sujit K, Petch-Udomsinsuk K, Leikul A, Tanwattana W, Pintawong W and Thongtip N 2005. Help and Care for an Asiatic Elephant Having Esophageal Obstruction : A case report. *Kamphaengsaen Acad J.* 3(3): 39 - 43.
- Raath JP 1993. Chemical capture of the African elephant, in McKenzie, AA (ed): *The Capture and Care Manual*. Wildlife Decision Support Services and South African Veterinary Foundation. pp 484-493.



## บทคัดย่อ

การวางยาสลบด้วย etorphine hydrochloride ร่วมกับ azaperone และคงการสลบด้วย isoflurane inhalation เพื่อส่องกล้อง endoscope ตรวจหลอดอาหารและกระเพาะช้างเอเชีย (*Elephas maximus*): รายงานสัตว์ป่วย

นิกร ทองทิพย์<sup>1,2\*</sup> อุมพร ไหมแก้ว<sup>4</sup> วัลยา ทิพย์กันทา<sup>3</sup> ดารกา ทองไทยนนท์<sup>3</sup> นิชารีย์ อินคำ<sup>6</sup> เบญจพล หล่อสัญลักษณ์<sup>1</sup>  
พรชัย สัตยฐิติเสรี<sup>1,2</sup> บริพัตร ศิริอรุณรัตน์<sup>3</sup> สุเมธ กมลนรนารถ<sup>3</sup>

ช้างเอเชียเพศเมียอายุ 30 ปี ถูกนำส่งเข้ารับการตรวจวินิจฉัยภาวะหลอดอาหารอุดตันที่โรงพยาบาลสัตว์มหาวิทยาลัยเกษตรศาสตร์ กำแพงแสน ช้างแสดงอาการคล้ายการสำรอกเศษอาหารประมาณสองสามวันก่อนส่งมารักษา กระบวนการวินิจฉัยเริ่มต้นด้วยการให้ยาซึม azaperone ขนาด 80 มก. ฉีดเข้ากล้ามเนื้อ ภายหลังจากที่ช้างแสดงอาการซึม ทำการใส่ชุดพยุงช้างที่ขาทั้งสี่ข้างและแขวนยัดกับสลิง และผูกสลิงยึดไว้กับตะขอของรถเครนขนาดใหญ่เพื่อพยุงน้ำหนักตัวของช้าง จากนั้นทำการให้ยาสลบ etorphine hydrochloride จำนวน 2 มก. (0.00066 มก.ต่อกก.) ฉีดเข้าเส้นเลือดดำที่ใบหู เมื่อช้างเริ่มแสดงอาการสลบโดยทิ้งน้ำหนักตัวลงบนชุดพยุงจึงค่อยๆปล่อยเครนให้ช้างลงนอน ตะแคงบนเบาะพองน้ำ ทำการให้ออกซิเจนโดยการสอดท่อเข้ารูวงทั้งสองข้าง ทำการสอดท่อช่วยหายใจเข้าหลอดลมโดยวิธี blind technique แต่เนื่องจากช้างยังไม่สลบลึกพอที่จะสอดท่อช่วยหายใจได้ ช้างแสดงอาการเคี้ยวปากเมื่อสัมผัสโคนลิ้น จึงฉีดยาสลบ etorphine hydrochloride เข้าเส้นเลือดดำเพิ่มอีกสองครั้ง (0.5 และ 1 มก.) จึงสามารถลดอาการเคี้ยวปากและสามารถสอดท่อช่วยหายใจได้สำเร็จ จากนั้นทำการสอดท่อช่วยหายใจเข้ากับเครื่องดมยาสลบ โดยใช้ยาดมสลบ isoflurane ขนาด 5% แต่อย่างไรก็ตามช้างยังคงแสดงอาการเคี้ยวปากอยู่จึงทำการฉีดยาสลบ etorphine hydrochloride (1 มก.) เข้าเส้นเลือดดำเพิ่มอีกหนึ่งครั้ง จึงสามารถหยุดการเคี้ยวปากของช้างได้ จากนั้นจึงทำการสอดกล้อง endoscope เพื่อตรวจการอุดตันของหลอดอาหารและกระเพาะของช้างได้ ภายหลังจากเสร็จสิ้นกระบวนการวินิจฉัย ได้ทำการฉีดยาแก้ฤทธิ์ยาสลบ naltrexone ขนาด 500 มก. เข้ากล้ามเนื้อขาหน้า และสามารถตรวจพบรีเฟล็กซ์ต่างๆ ได้ภายในเวลาหนึ่งนาที จากนั้นเมื่อครบสองนาทีช้างเริ่มแสดงอาการเคี้ยวปากจึงทำการดึงท่อช่วยหายใจออก ช้างลุกขึ้นยืนได้ในเวลาสามนาที และช้างสามารถยืนได้ด้วยตัวเองในเวลาแปดนาที และสามารถถอดชุดพยุงและเดินเองได้ในเวลาสิบเอ็ดนาที รวมเวลาทั้งหมดในการทำงานตั้งแต่วางยาซึมจนช้างเดินได้เป็นเวลาทั้งสิ้นหนึ่งชั่วโมงสิบหกนาที

คำสำคัญ: การวางยาสลบ, ช้าง, หลอดอาหารอุดตัน

<sup>1</sup>หน่วยสัตว์ป่า โรงพยาบาลมหาวิทยาลัยเกษตรศาสตร์กำแพงแสน คณะสัตวแพทยศาสตร์ มหาวิทยาลัยเกษตรศาสตร์ วิทยาเขตกำแพงแสน จ.นครปฐม ประเทศไทย 73140

<sup>2</sup>ภาควิชาเวชศาสตร์คลินิกสัตว์ใหญ่และสัตว์ป่า คณะสัตวแพทยศาสตร์ มหาวิทยาลัยเกษตรศาสตร์ วิทยาเขตกำแพงแสน จ.นครปฐม ประเทศไทย 73140

<sup>3</sup>สำนักอนุรักษ์วิจัยและการศึกษา องค์การสวนสัตว์ กรุงเทพฯ

<sup>4</sup>สวนสัตว์เปิดเขาเขียว อ.ศรีราชา จ.ชลบุรี ประเทศไทย

<sup>5</sup>คณะสัตวแพทยศาสตร์ มหาวิทยาลัยเทคโนโลยีราชมงคลภาคตะวันออก อ.ศรีราชา จ.ชลบุรี ประเทศไทย

<sup>6</sup>โรงพยาบาลปศุสัตว์และสัตว์ป่า คณะสัตวแพทยศาสตร์ มหาวิทยาลัยมหิดล อ.ไทรโยค จ.กาญจนบุรี ประเทศไทย

\*ผู้รับผิดชอบบทความ E-mail: fvetnit@ku.ac.th, nthongtip@yahoo.com